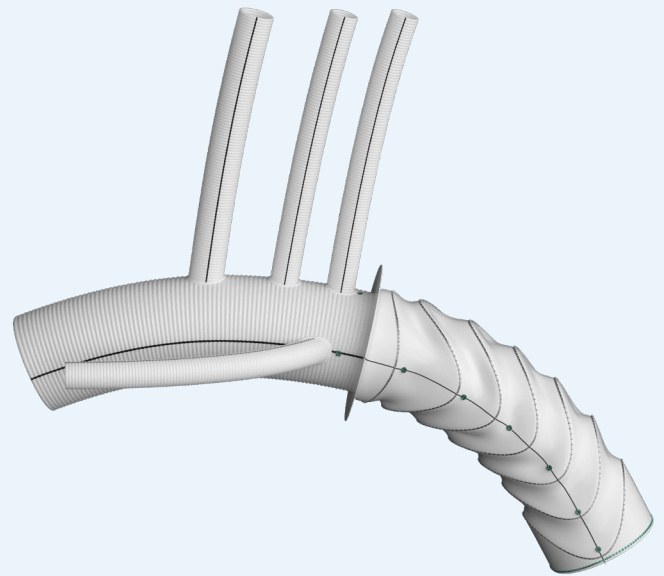


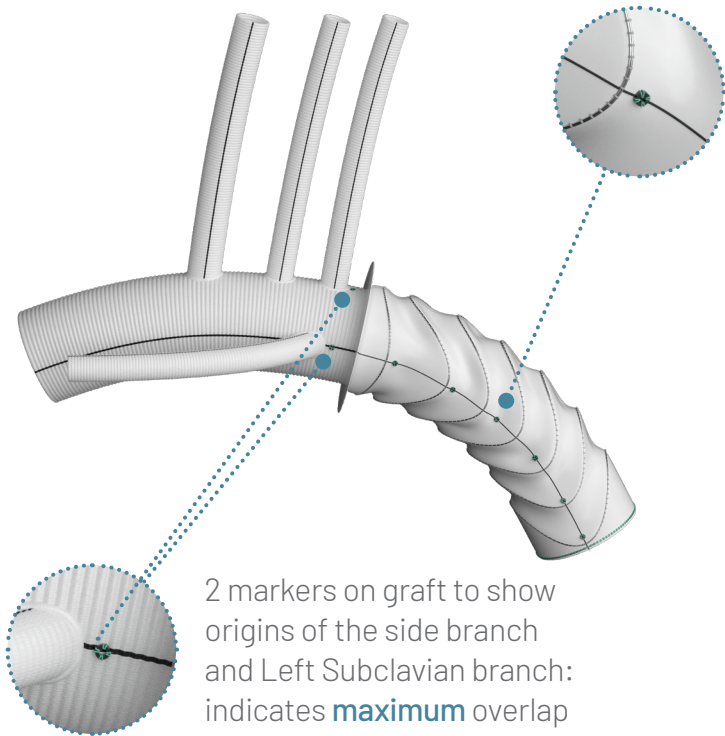
# **thoraflex™ hybrid**

Conforming Arch  
Surgery to the  
Gold Standard



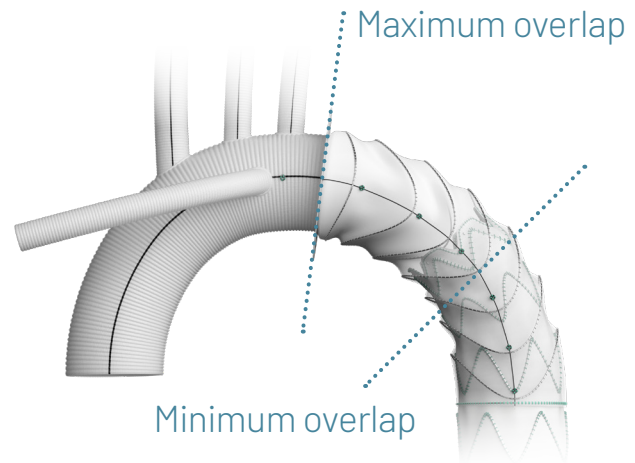
# Clearly Marked: Extending with Confidence

Tantalum radiopaque markers: accuracy for endovascular reintervention



2 markers on graft to show origins of the side branch and Left Subclavian branch: indicates **maximum** overlap limit for TEVAR extension.

Stent graft markers positioned 20mm apart. Minimum overlap for Relay® Pro NBS TEVAR extension is 3 covered stents or 50mm (per IFU).



*“The radiopaque markers in the stented portion of the Thoraflex prosthesis further **simplify endovascular completion** when necessary.”<sup>1</sup>*

Visibly identifiable markers

Accurate device positioning

Safe and effective endovascular intervention


Clinical benefits to the surgeon & patient

1. Ruggieri et al. (2015). 'Multibranch hybrid device for frozen elephant trunk: what does it change?' *Journal of Thoracic & Cardiovascular Surgery*. 15(1), pp253-255.

# True Guidance: Ensuring Accurate Placement

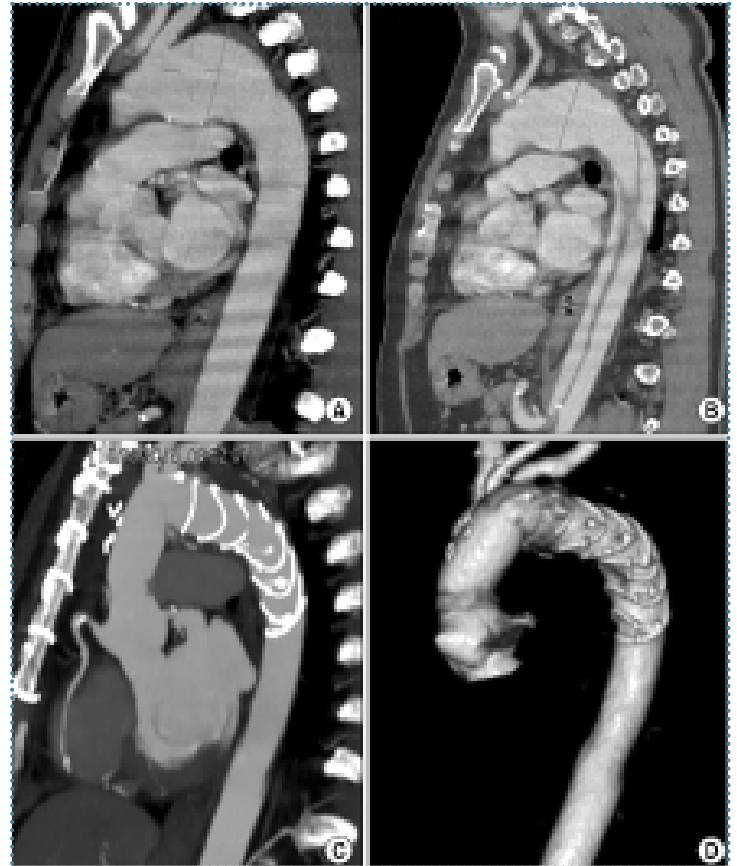Guidewire positioning: targeting the true lumen of the dissected thoracic aorta

- ▶ Thoraflex™ Hybrid delivery system tip offers the choice of 2x guidewire access ports.
- ▶ Facilitates direct tracking within the distal thoracic aorta using a guidewire.



*“The entire aorta must be carefully investigated before the operation; especially in cases of acute or chronic dissection, it is mandatory to know the origin of the visceral arteries (true or false lumen) and the presence and the localization of the distal re-entry sites.”<sup>2</sup>*

**100%**  
Successful  
Deployment/  
Placements<sup>3</sup>  
*(181/181 cases)*



CT scan image showing chronic aortic arch aneurysm and type B acute dissection treated with Thoraflex™ Hybrid. (A/B =Preoperative, C/D =Postoperative results).<sup>2</sup>



Discover solutions for every segment of the aorta  
[terumoaortic.com](https://www.terumoaortic.com)



LinkedIn



VuMedi



X